

## Are some strokes preventable? The potential role of transcranial doppler in transient ischaemic attacks of carotid origin

Christopher H E Imray, Carl A S Tiivas

*Lancet Neurol* 2005; 4: 580–86

Coventry and Warwickshire  
County Vascular Unit  
(C H E Imray FRCS), Clinical  
Physics and Biomedical  
Engineering Department  
(C A S Tiivas MSc), University  
Hospital Coventry and  
Warwickshire NHS Trust,  
Coventry, UK

Correspondence to:  
Dr Christopher H E Imray,  
Coventry and Warwickshire  
County Vascular Unit, University  
Hospitals Coventry and  
Warwickshire NHS Trust,  
Coventry CV2 2DX, UK  
chrisimray@aol.com

Transient ischaemic attacks (TIA) are more than just ministrokes. The high frequency of early stroke following TIA has resulted in the recent publication of guidelines in the UK. The guidelines recommend that patients attend a neurovascular clinic within 7 days of the index event to expedite investigation and treatment and so reduce the risk of a subsequent (potentially more serious) neurological event. After a TIA or stroke caused by carotid-artery disease, there is an increase in cerebral microemboli detectable by transcranial doppler (TCD). High microembolic loads appear to be surrogate markers for future neurological events, and the pharmacological efficacy of therapeutic interventions can now be rapidly and non-invasively assessed in the clinic or at the bedside. Medical treatments can now be optimised, avoiding the need for urgent or emergency carotid surgery and therefore allowing patients to undergo safer elective surgery when appropriate.

### Introduction

The risk of stroke after a hemispheric transient ischaemic attack (TIA) is greatest within the first 72 h, and event rates as high as 20% within the first month have been reported.<sup>1</sup> The Royal College of Physicians' National Clinical Guidelines for Stroke (2004) recommend that patients who have a TIA or minor stroke should be seen in a specialist neurovascular clinic within 7 days, and those with more than one TIA in a week should be admitted and investigated immediately.<sup>2</sup> The type, frequency, duration, and severity of a TIA are predictors of subsequent risk and severity of future strokes. All patients with a history of clear focal neurological deficit merit investigation, but those with motor or speech deficits have a more serious prognosis than those patients with sensory or short-lived deficits. There is also evidence that after an anterior-circulation TIA (resulting from a carotid stenosis) there is a high risk of early stroke.<sup>1,3–5</sup>

What should the next step be? Duplex ultrasonographic examination may confirm a critical internal-carotid-artery stenosis, and CT or magnetic resonance angiography (MRA) will exclude haemorrhagic stroke in most cases. If cardiac-rhythm or valvular problems are found, they can be addressed. Antiplatelet agents can be introduced or adjusted; and blood pressure, glycaemic, and lipid profiles can be modified. However, is this enough? If the patient continues to have further focal events, or a neurological deficit persists, should anything more be done? How can the efficacy of various treatments be assessed, and when is it safest to proceed with surgery?

### Transcranial doppler and transient microembolic signals

Transcranial doppler (TCD) is a non-invasive ultrasound-based technique used to measure blood velocity within the large vessels of the cerebral arterial circulation. The middle cerebral artery is insonated with a 2 MHz pulsed signal transmitted through the temporal

bone to a depth of 4·5–6·0 cm. The signal is reflected by solid components of blood (mostly red blood cells) and distorted according to the doppler-shift principle. The reflected waveform gives information about systolic, diastolic, and mean blood-flow velocity.

Gaseous or solid microemboli within the middle cerebral artery can be detected with TCD as high-intensity transient signals, also known as cerebral microembolic signals. Microemboli are defined as having a duration of less than 300 ms and an amplitude that is 3 dB higher than the background blood-flow signal.<sup>6</sup> Such signals are unidirectional and occur randomly within the cardiac cycle. Furthermore, most microemboli are easily recognised since they produce a characteristic sound (chirp). An individual microembolic signal does not cause neurological symptoms but may represent an early warning sign that an individual is at a greater risk of a neurological event in the near future.

### Potential role for TCD in management of TIA of carotid origin

Patients with crescendo or recurrent TIAs seem to be at particularly high risk of subsequent stroke. The findings of a large, multicentre, non-selected, observational study emphasises the “not so benign” prognosis for all TIA patients.<sup>7</sup> The reported frequency of stroke after an index TIA is higher than was originally thought and the prevalence ranges from 5% within the first 2 days and 20% within the first month<sup>1</sup> to 10·5% within 90 days.<sup>3</sup> Perhaps the greatest justification for early investigation and treatment of symptomatic carotid-artery disease comes from the analysis of the pooled data from the ECST and NASCET trials. The benefit from surgery was greatest for patients undergoing surgery within 2 weeks of their last ischaemic event.<sup>8</sup>

### Natural course of microemboli and TIA

TCD-detected transient microembolic signals are common for some days after an acute stroke.<sup>9</sup>

Microemboli are an important independent predictor of early ischaemic recurrence in patients with stroke or TIA of arterial origin.<sup>10</sup> In a study of 69 patients with symptomatic carotid stenoses,<sup>11</sup> microemboli were detected more frequently when the patients were examined soon after symptoms of cerebral ischaemia. Several other studies have shown a link between persistent cerebral microembolisation and the risk of future TIA or stroke.<sup>12–14</sup> In symptom-free patients with a critical internal-carotid-artery stenosis, when the microembolic signal rate was greater than two per hour in the ipsilateral middle cerebral artery, there was an associated increased risk of developing ischaemia (odds ratio 31 [95% CI 3–302],  $p=0.005$ ).<sup>11</sup> The presence of microemboli may define a sub-group of patients with critical stenoses who might be at greater risk of having a stroke.<sup>15</sup>

#### Effect of antiplatelet agents on microemboli

Goertler and colleagues<sup>16</sup> have assessed the efficacy of intravenous aspirin in controlling microemboli. Nine patients with recent symptoms arising from a critical internal-carotid-artery stenosis underwent TCD monitoring for 1 h; they were then given intravenous aspirin (500 mg), and the TCD measurements were repeated. In most patients, there was a reduction in the number of microemboli within 30 min; however, one patient showed no sustained decrease in the number of microemboli and later had an ischaemic event. In a further study by the same group,<sup>17</sup> 74 patients with symptomatic critical internal-carotid-artery stenosis underwent 1 h of bilateral TCD monitoring within a month of their symptoms. 38 (51%) patients had detectable emboli. Among 48 receiving aspirin 19 (40%) had microembolic signals and among 26 not receiving aspirin 18 (70%) had detectable microemboli. TCD-detected emboli were controlled in about half of the patients on maximum medical therapy, whereas in the others persistent embolisation was an independent predictor of recurrent TIA or stroke (adjusted odds ratio 37.0 [95% CI 3.5–333],  $p<0.003$ ).

Junghans and Siebler<sup>18</sup> described rapid control of microemboli with the glycoprotein IIb/IIIa inhibitor (Tirofiban) in 24 patients with recent cerebral or retinal embolism of arterial origin. With Tirofiban, the microembolic signal rate dropped from a median of 38 per hour (range 9–324) to zero in all patients. After the infusion was stopped the inhibitory effect of Tirofiban was found to be reversible, with a significant increase in microembolic signals (median 13.5 [range 0–35],  $n=16$ ;  $p<0.001$ ). Six patients received overlapping oral antiplatelet agents and no microemboli were detected. Junghans and Siebler concluded that cerebral microemboli of arterial origin have the properties of solid emboli—with platelet-fibrinogen units as predominant constituent parts—and that glycoprotein IIb/IIIa inhibitors might have the

potential to reduce the risk of a subsequent ischaemic event in patients with unstable carotid disease. Tirofiban can also inhibit the extension of microthrombosis, which might occur after arterial occlusion by emboli.

In the CARESS trial,<sup>19</sup> 230 patients with at least 50% carotid stenosis and ipsilateral carotid-territory symptoms were screened with TCD for microemboli. Of the 110 patients with microemboli, 107 were randomly assigned to either the dual antiplatelet therapy of aspirin and clopidogrel, or aspirin alone. On day 7, the dual-therapy group ( $n=51$ ) had more effective control of microembolic signals than the group assigned single antiplatelet therapy ( $n=56$ ). There were four recurrent strokes and seven TIAs in the single-therapy group, and four TIAs in the dual-therapy group over 7 days.

#### Practicalities of TCD emboli detection

An ambulatory TCD system has been developed; it works by using an autosearch algorithm to restore vessel insonation if the quality of signals decreases.<sup>20</sup> Patients can now be monitored continuously for up to 5 h, and in view of the likely temporal variability in embolisation, the technique is likely to improve the predictive value of microemboli detection. However, Blaser and colleagues<sup>21</sup> found that monitoring periods shorter than 1 h did not pick up less clinically relevant information when signal frequency was already either high or low. Cerebral perfusion has been assessed in individuals undergoing a maximum exercise test at an altitude of 5260 m,<sup>22</sup> showing that TCD monitoring is a simple and robust investigation. As such, there is no reason why the technique should not be more widely available within a general hospital setting, and it should not be seen as an investigation that is only available within specialist units.

#### Surgery for symptomatic carotid-artery disease

Several prospective randomised trials in patients with symptomatic critical internal-carotid-artery stenosis have shown that carotid endarterectomy combined with medical therapy is better than medical therapy alone (>70%).<sup>23–25</sup> However, in patients with multiple, recurrent, or crescendo TIA, there is little information on optimum management. The treatment options generally adopted are intravenous heparin and urgent surgery. Mentzer and colleagues described 12 patients with crescendo TIA.<sup>26</sup> Seven patients underwent emergency carotid endarterectomy, and none had major complications; but of the five patients who did not have surgery, three patients had strokes and one died of cerebral infarction. In the Veterans Affairs trialists study,<sup>27</sup> patients with recent TIA or minor stroke were randomly assigned to either surgery or best medical therapy. At 1 year the proportion of patients with subsequent stroke or crescendo TIA was significantly lower among the 91 who received carotid

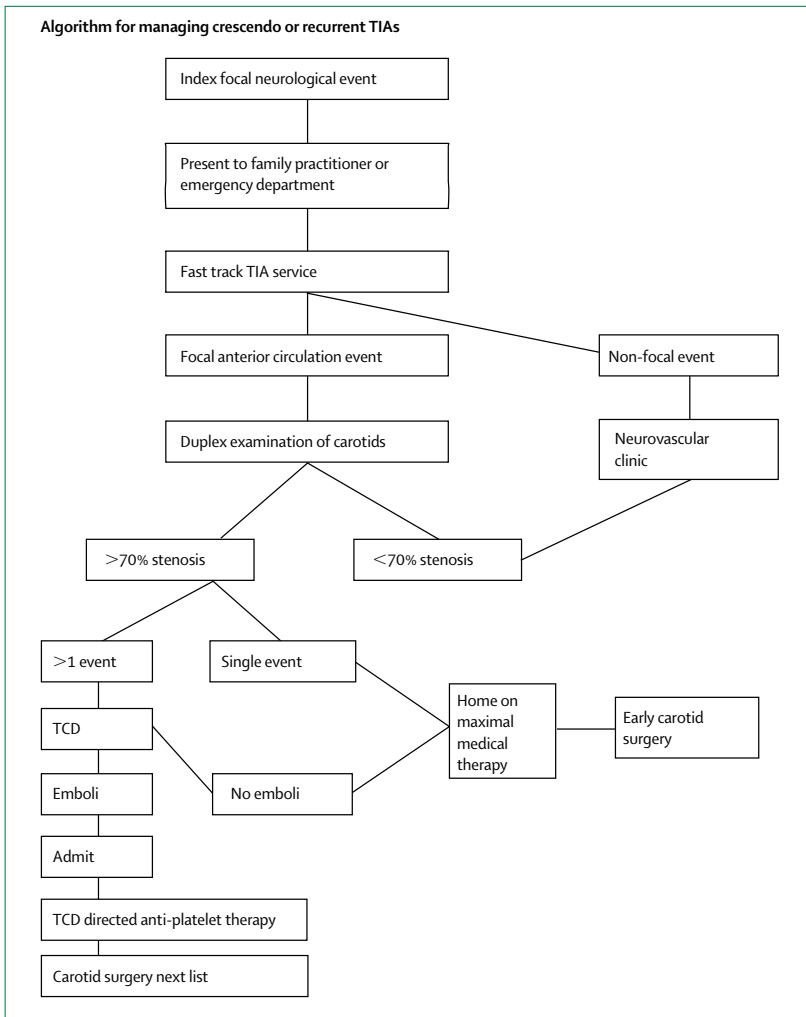


Figure 1: Algorithm for managing crescendo or recurrent TIA<sup>38</sup>

endarterectomy than among the 98 patients who did not undergo surgery (8% vs 19%;  $p=0.011$ ). Of the 98 patients initially treated medically, 12 subsequently developed crescendo TIA, four had minor strokes, and three had major strokes. All 12 patients with crescendo TIA then underwent uncomplicated urgent carotid endarterectomy. In another study 29 patients with repeated TIAs were treated with heparin until elective carotid surgery was undertaken.<sup>28</sup> There was a mean wait of 5 days for surgery, and during heparin treatment there were two carotid occlusions and 13 patients continued to have further TIAs. Postoperatively there was one stroke and one death due to myocardial infarction. On the basis of the poor outcome in patients treated with drugs only,<sup>27</sup> a more aggressive approach with urgent surgical intervention has been advocated. However, the published results of urgent carotid surgery are variable,<sup>27,29–34</sup> with complication rates ranging from no deficits in 12 patients to operative mortalities as high as 20% and

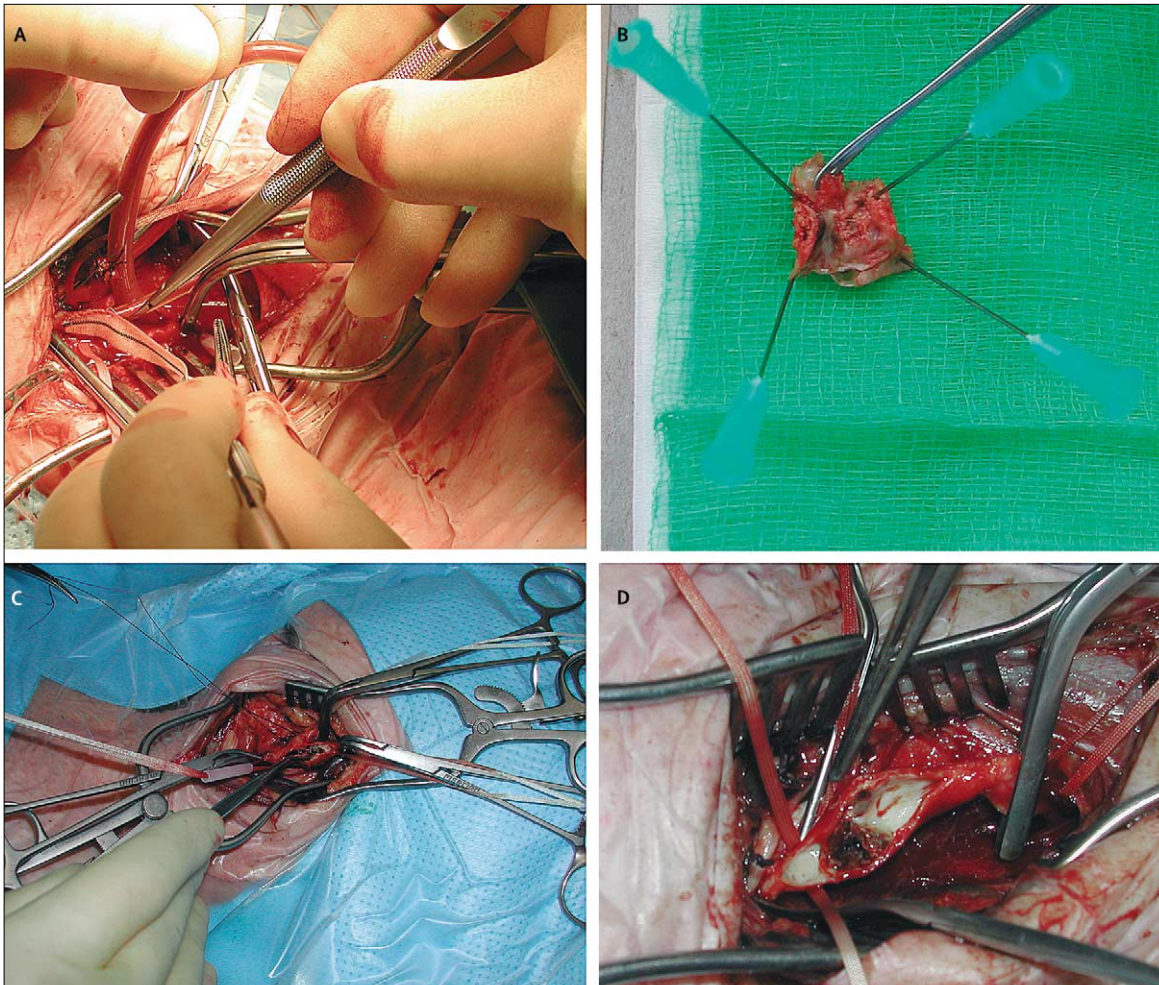
neurological deficits in up to 40% in some other series. A systematic review<sup>35</sup> of the risks of carotid endarterectomy in relation to both the clinical indication for and timing of surgery showed that urgent carotid surgery for evolving symptoms results in a much higher risk of stroke or death (19.2% [95% CI 10.7–27.8]) than surgery for stable symptoms (odds ratio 3.9 [95% CI 2.7–5.7],  $p<0.001$ ; 13 studies). In view of the fact that both medical treatment and emergency carotid surgery have substantial complication rates, is there an alternative approach?

### Preoperative TCD

The role of TCD before surgery has been explored in small trials in specialised centres but currently there is no level 1 evidence to support its use. Patients who recently had TIA or stroke associated with high-grade carotid stenosis and ipsilateral haemodynamic compromise with exhausted reactivity to carbon dioxide on TCD had a greater risk of early stroke before surgery than those with normal haemodynamics.<sup>36</sup>

Embolisation detected by TCD after recent neurological symptoms in carotid stenosis predicts the short-term ipsilateral stroke risk. TCD has been used to identify patients who are at high risk of a further event; Markus and MacKinnon<sup>37</sup> have argued that these patients should undergo urgent endarterectomy.

The timing of carotid surgery in patients with recurrent or crescendo TIA can be safely altered;<sup>38</sup> 19 patients were treated with a combination of TCD-directed medical therapy and elective surgery. After a TIA, patients were assessed as outpatients in the vascular laboratory, and each patient was questioned about any focal neurological symptoms in the previous 4 weeks (hemisensory, hemimotor, dysphasia, or amaurosis fugax). All patients then underwent a routine carotid duplex, and those with more than one focal event and an appropriate-sided critical internal-carotid stenosis underwent 1 h of TCD monitoring of the symptomatic middle cerebral artery. Patients with more than one focal event and microembolic signals were admitted to hospital. Maximum oral medical therapy was started, and a TCD-directed intravenous infusion of the antiplatelet agent dextran 40 was started. The infusion was increased incrementally until there were no microembolic signals. Sustained embolisation seemed to be associated with the development of neurological events since no patient had symptoms once the emboli were controlled. A single embolus does not cause a TIA or stroke, but a high embolic load seems to indicate that the individual is at greater risk of further focal neurological events. Patients underwent further TCD examinations to confirm that embolisation had ceased, and carotid endarterectomy was undertaken on the next elective operating list up to 10 days later (figure 1). This delay has the advantage of moving high-risk surgery out of the emergency setting and into



**Figure 2: Surgical technique and carotid plaque appearance**

A: right carotid endarterectomy with shunt in situ. B: carotid plaque with platelet frond from a symptomatic patient. C and D: intraoperative photographs of a symptomatic carotid plaque.

elective hours with independently demonstrated lower complication rates.<sup>35</sup> Therefore, safe interhospital transfer could be considered.

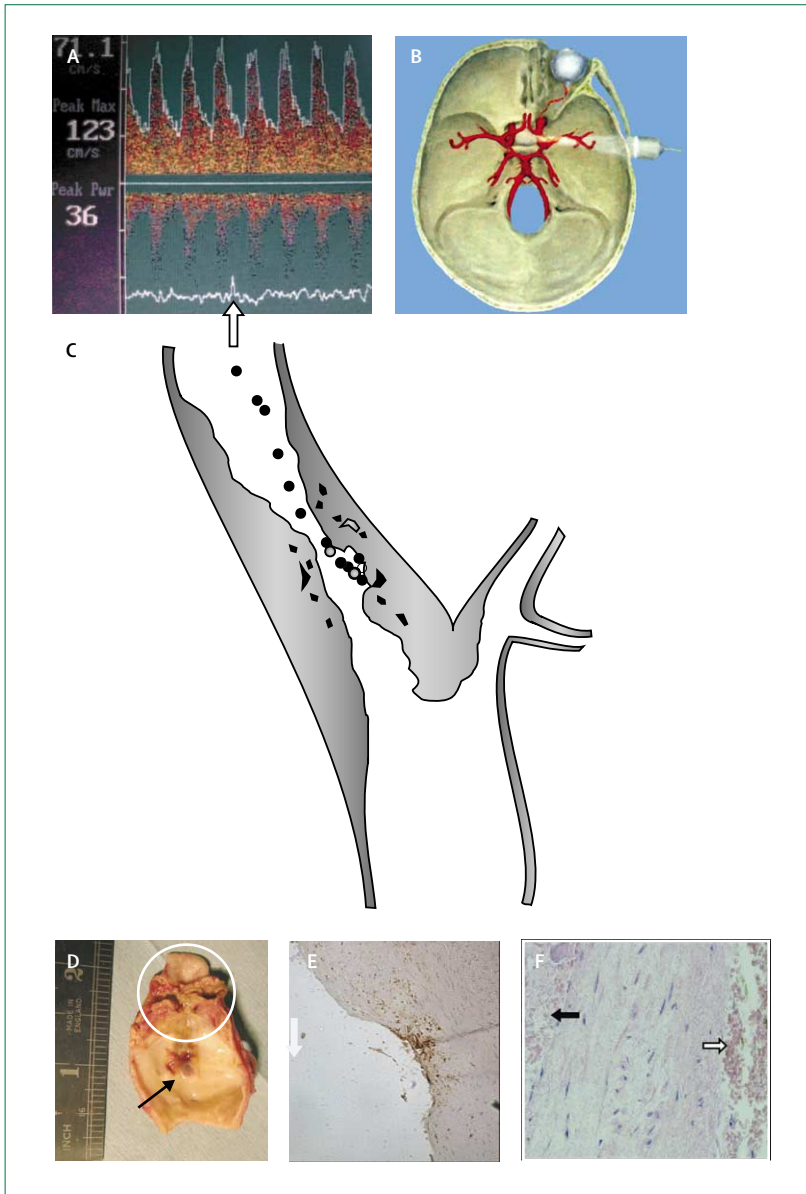
#### Intraoperative TCD

Historically, TCD was first used during carotid surgery to help assess the need for shunting during the cross clamp phase.<sup>39</sup> Among 1058 patients, a large decrease in velocity (greater than 90%) in the middle cerebral artery was associated with operative stroke (odds ratio 3.3, [1.3–8.3]).<sup>40</sup> Subsequently, TCD has also been used to measure the intraoperative microembolic load.<sup>41,42</sup> TCD sensitivity to the presence of particulate emboli can help guide surgical dissection of the carotid artery before endarterectomy. Jansen and colleagues<sup>43</sup> found that a high microembolic load was significantly related to new ischaemic lesions. Intraoperatively, detection of emboli by TCD has been used to modify surgical techniques or

strategies; for example, early clamping of the internal carotid artery when there is a high embolic load (figure 2).<sup>44,45</sup>

#### Postoperative TCD

The reported rate of early postoperative carotid thrombosis is 2–3%.<sup>46,47</sup> After carotid endarterectomy, TCD-detected microemboli are thought to be platelet aggregates generated by a partly denuded and highly thrombogenic vascular endothelium. Unchecked, these aggregates can mature into occlusive thromboemboli, resulting in infarcts in the succeeding hours or days. In the early postoperative phase (after carotid endarterectomy) if microembolic counts are greater than 50 per hour, this can help predict the development of ipsilateral focal ischaemia.<sup>48,49</sup> Lennard and colleagues<sup>50</sup> eliminated all postoperative strokes with the aid of a 3 h TCD monitoring session. They found that signs of persistent embolisation of at least 25 microemboli signals



**Figure 3: Composite schematic of symptomatic carotid-artery stenosis**  
 High intensity transient signal (A, arrow) detected on transcranial doppler insonation of the middle cerebral artery via a temporal window using a 2 MHz probe (B). Carotid bifurcation with atherosclerotic plaque (C) causing >70% stenosis. Emboli originating from surface ulcer or plaque rupture shower the cerebral circulation. Carotid plaque showing surface ulceration (C, right; D, arrow) and disruption of media with intraplaque haemorrhage (D, circle). Microscopy of unstable plaque with subendothelial macrophage accumulation (E; CD68 stain light microscopy,  $\times 100$ ); and intraplaque haemorrhage (F, black arrow) and ulcerated surface with overlying erythrocytes (F, white arrow; haematoxylin and eosin light microscopy,  $\times 200$ ).

in 10 min consistently preceded injury. Embolisation was completely abolished with incremental infusion of the antiplatelet agent (dextran 40). The same group has now audited 600 consecutive carotid endarterectomies, after the introduction of TCD-directed dextran therapy and found that the rate of postoperative thrombotic strokes fell from 2.7% to 0%.<sup>46,47</sup> There is evidence that 30 min of postoperative TCD monitoring is adequate.<sup>51</sup>

### Possible mechanisms of cerebral microemboli generation

In patients with symptomatic critical internal-carotid-artery stenoses, there is likely to be an acute rupture of an atherosclerotic internal carotid plaque with superimposed thrombosis—not dissimilar to the acute coronary syndrome. A period of instability and increased activity within the carotid plaque is indicated by an increase in cerebral microemboli signals that can be detected in the middle cerebral artery. Microemboli appear to be primarily solid platelet aggregates, since they have been controlled with various antiplatelet agents including intravenous aspirin,<sup>16,17</sup> dextran 40,<sup>46–51</sup> Tirofiban,<sup>18</sup> and S-nitrosoglutathione.<sup>52</sup> In 100 patients, use of clopidogrel (75 mg) preoperatively resulted in a large reduction in the relative risk of having 20 or more emboli in the postoperative period (odds ratio 10.23 [1.3–83.3];  $p=0.01$ ).<sup>53</sup> Plaque stabilisation with aspirin and glycoprotein IIb/IIIa inhibitors are established therapies for the acute coronary syndrome (figure 3).

### Efficacy of pharmacological therapy

Cerebral microemboli seem to be surrogate markers for future ischaemic events. If they persist despite medical therapy, the risk of further neurological events is about 40 times higher than if they do not.<sup>17</sup> The CARESS trial<sup>19</sup> showed that dual therapy with clopidogrel and aspirin controls both microemboli and symptoms more effectively than single therapy. However, even in the dual-therapy group, some patients had continued embolisation and remained at risk of further events.

### Identification of high-risk patients and timing of subsequent surgery

A case could be made for the use of TCD emboli detection in all carotid-based TIA, but at present this approach is not practicable. Some researchers believe that patients with continued embolisation should be offered urgent surgery.<sup>37</sup> However, cessation of both microemboli and symptoms in patients with recurrent or crescendo TIA has been described with use of TCD-directed intravenous antiplatelet agents.<sup>38</sup> Consequently, patients can undergo carotid endarterectomy safely on the next elective list, avoiding the risks associated with urgent or emergency surgery<sup>35</sup> or the risks associated with delay when microemboli persist despite oral antiplatelet therapy.<sup>9,19</sup>

### Conclusion

Until further studies are undertaken, in our opinion all patients presenting with TIA or minor stroke should undergo rapid clinical assessment and duplex examination to assess the state of the internal carotid arteries (ideally within 24–48 h). A patient with a critical internal carotid stenosis and more than one TIA should have a TCD study to look for microemboli in the

**Search strategy and selection criteria**

References for this review were identified by searches of PubMed from 1980 until June 2005 with the terms TIA, microemboli, transcranial Doppler, TCD, crescendo TIA, recurrent TIA. Articles were also identified through searches of authors' own files. Only papers published in English were reviewed.

appropriate middle cerebral artery. Those with critical internal carotid stenosis, symptoms, and emboli should be admitted to stroke prevention and care units. These units would be similar to coronary-care units and jointly managed by stroke physicians, neurologists, and vascular surgeons. With a high ratio of staff to patients, frequent corrections of cardiovascular, metabolic, and haematological factors could be achieved, the aim being to prevent strokes from occurring.<sup>54,55</sup> Elective surgery is likely to have better outcomes than either the conventional treatments of medical therapy alone or urgent surgery. Failure to control either microemboli or symptoms from a critical internal-carotid stenosis remains an indication for urgent surgery. Although intravenous heparin decreases cerebral microemboli after a focal event,<sup>9</sup> the widely adopted approach of intravenous heparin and early surgery is unsatisfactory.<sup>28</sup>

Converging lines of evidence suggest that TCD can assist in identifying the patients at high risk of a subsequent neurological event, and the pharmacological efficacy of therapeutic interventions can now be assessed rapidly and non-invasively. TCD detection of cerebral microemboli offers an important advance in multidisciplinary team working which enables the physician to optimally integrate medical therapies and the surgeon to determine the safest timing of surgery for a patient who has had a recent TIA or stroke.

**Acknowledgments**

D J Higman, C Marshall, A J Sinclair, and N Balcombe (UHCW NHS Trust, Coventry, UK), K Pattinson (John Radcliffe Hospital, Oxford, UK), and C W M Chan (Queen Elizabeth Hospital, Birmingham, UK).

**Authors' contributions**

CI did the literature search, devised figures, and wrote the review. CT did an additional literature search and helped review and amend the paper.

**Conflicts of interest**

We have no conflicts of interest.

**Role of the funding source**

No funding source was involved in the preparation of this paper.

**References**

- Coull A, Lovett J, Rothwell P. Population based study of early risk of stroke after transient ischaemic attack or minor stroke: implications for public organisation of services. *BMJ* 2004; **328**: 326–28.
- Royal College of Physicians. National clinical guidelines for stroke, 2nd edn. Sudbury, Suffolk: Laverham Press, 2004: 31.
- Johnston SC, Gress DR, Browner WS, Sidney S. Short-term prognosis after emergency department diagnosis of TIA. *JAMA* 2000; **284**: 2901–06.
- Rothwell PM, Eliasziw M, Gutnikov SA, Warlow CP, Barnett HJ. Endarterectomy for symptomatic carotid stenosis in relation to clinical subgroups and timing of surgery. *Lancet* 2004; **363**: 915–24.
- Rothwell PM, Warlow CP. Timing of TIAs preceding stroke: time window for prevention is very short. *Neurology* 2005; **64**: 817–20.
- Consensus Committee of the Ninth International Cerebral Hemodynamic Symposium. Basic identification criteria of Doppler microembolic signals. *Stroke* 1995; **26**: 1123.
- Daffertshofer M, Mielke O, Pullwitt A, Felsenstein M, Hennerici M. Transient ischaemic attacks are more than "ministrokes". *Stroke* 2004; **35**: 2453–58.
- Rothwell PM, Eliasziw M, Gutnikov SA, Warlow CP, Barnett HJM. Endarterectomy for symptomatic carotid stenosis in relation to clinical subgroups and timing of surgery. *Lancet* 2004; **363**: 915–24.
- Sliwka U, Lingnau L, Stohlmann WD, et al. Prevalence and time course of microembolic signals in patients with acute stroke. *Stroke* 1997; **28**: 358–63.
- Valton L, Larrue V, Pavy le Traon A, Massabuau P, Geraud G. Microembolic signals and risk of early recurrence in patients with stroke or transient ischaemic attack. *Stroke* 1998; **29**: 2125–28.
- Forteza AM, Babikian VL, Hyde C, Winter M, Pochay V. Effect of time and cerebrovascular symptoms on the prevalence of microembolic signals in patients with cervical carotid stenosis. *Stroke* 1996; **27**: 687–90.
- Babikian VL, Hyde C, Winter MR. Cerebral microembolism and early recurrent cerebral or retinal ischemic events. *Stroke* 1997; **28**: 1314–18.
- Molloy J, Markus HS. Asymptomatic embolization predicts stroke and TIA risk in patients with carotid artery stenosis. *Stroke* 1999; **30**: 1440–43.
- Gao S, Wong KS, Hansberg T, Lam WW, Droste DW, Ringelstein EB. Microembolic signal predicts recurrent cerebral ischaemic events in acute stroke patients with middle cerebral artery stenosis. *Stroke* 2004; **35**: 2832–36.
- Siebler M, Nachtmann A, Sitzer M, et al. Cerebral microembolism and the risk of ischemia in asymptomatic high-grade internal artery stenosis. *Stroke* 1995; **26**: 2184–86.
- Goertler M, Baeumer M, Kross R, et al. Rapid decline of cerebral microemboli of arterial origin after intravenous acetylsalicylic acid. *Stroke* 1999; **30**: 66–69.
- Goertler M, Blaser T, Krueger S, Hofmann K, Baeumer M, Wallesch C-W. Cessation of embolic signals after antithrombotic prevention is related to reduced risk of recurrent arterioembolic transient ischaemic attack and stroke. *J Neurol Neurosurg Psychiatry* 2002; **72**: 338–42.
- Junghans U, Siebler M. Cerebral microembolism is blocked by tirofiban, a selective non-peptide platelet glycoprotein IIb/IIIa receptor antagonist. *Circulation* 2003; **107**: 2717–21.
- Markus HS, Droste DW, Kaps M, et al. Dual antiplatelet therapy with clopidogrel and aspirin in symptomatic carotid stenosis evaluated using Doppler embolic signal detection. *Circulation* 2005; **111**: 2233–40.
- Mackinnon AD, Aaslid R, Markus HS. Long-term ambulatory monitoring for cerebral emboli using transcranial Doppler ultrasound. *Stroke* 2004; **35**: 73–78.
- Blaser T, Glanz W, Krueger S, Wallesch CW, Kropf S, Goertler M. Time period of monitoring for transcranial Doppler of embolic signals to predict recurrent risk of embolic transient ischaemic attack and stroke from arterial stenosis. *Stroke* 2004; **35**: 2155–59.
- Imray CHE, Myers SD, Pattinson KTS, et al. Effect of exercise on cerebral perfusion in humans at high altitude. *J Appl Physiol* 2005; **99**: 699–706.
- North American Symptomatic Carotid Endarterectomy Trial Collaborators: Beneficial effect of carotid endarterectomy in patients with high-grade carotid stenosis. *N Engl J Med* 1991; **325**: 445–53.
- European Carotid Surgery Trialists' Collaborative Group. MRC European Carotid Surgery Trial: Interim results for symptomatic patients with severe (70–99%) or mild (0–29%) carotid stenosis. *Lancet* 1991; **337**: 1235–43.
- Mayberg MR, Wilson, SE, Yatsu F, et al. Carotid endarterectomy and prevention of cerebral ischemia in symptomatic carotid stenosis: Veterans Affairs Co-operative Studies Program 309 Trialist Group. *JAMA* 1991; **266**: 3332–33.
- Mentzer RM, Finkelmeier BA, Crosby IK, Wellons HA. Emergency carotid endarterectomy for fluctuating neurologic deficits. *Surgery* 1981; **89**: 60–66.

- 27 Wilson SE, Mayberg MR, Yatsu F, Weiss DG. Crescendo transient ischemic attacks: a surgical imperative. *J Vasc Surg* 1993; **17**: 249–55.
- 28 Nehler MR, Moneta GL, McConnell DB, et al. Anticoagulation followed by elective carotid surgery in patients with repetitive transient ischemic attacks and high-grade stenosis. *Arch Surg* 1993; **128**: 1117–21.
- 29 Goldstone J, Moore WS. Emergency carotid artery surgery in neurologically unstable patients. *Arch Surg* 1976; **111**: 1284–91.
- 30 Schneider C, Johansen K, Konigstein R, Metzner C, Oettinger W. Emergency carotid thromboendarterectomy: safe and effective. *World J Surg* 1999; **23**: 1163–67.
- 31 Brandl R, Brauer RB, Maurer PC. Urgent carotid endarterectomy for stroke in evolution. *Vasa* 2001; **30**: 115–21.
- 32 Greenhalgh RM, Cuming R, Perkin GD, McCollum CN. Urgent carotid surgery for high-risk patients. *Eur J Vasc Surg* 1993; (suppl A): 25–32.
- 33 Eckstein HH, Schumacher H, Klemm K, et al. Emergency carotid endarterectomy. *Cerebrovasc Dis* 1999; **9**: 270–81.
- 34 Gertler JP, Blankenstein JD, Brewster DC, et al. Carotid endarterectomy for unstable and compelling neurologic conditions: do the results justify an aggressive approach? *J Vasc Surg* 1994; **19**: 42–40.
- 35 Bond R, Rerkasem K, Rothwell PM. Systematic review of the risks of carotid endarterectomy in relation to the clinical indication for and timing of surgery. *Stroke* 2003; **34**: 2302–03.
- 36 Blaser T, Hofmann, Buerger T, Effenberger O, Wallesch C-W, Goertler M. Risk of stroke, transient ischaemic attack, and vessel occlusion before endarterectomy in patients with symptomatic severe carotid stenosis. *Stroke* 2002; **33**: 1057–62.
- 37 Markus HS, MacKinnon A. Asymptomatic embolization detected by Doppler ultrasound predicts stroke risk in symptomatic carotid artery stenosis. *Stroke* 2005; **36**: 971–75.
- 38 Lennard NS, Vijayasekar C, Tiivas C, Chan CWM, Higman DJ, Imray CHE. Control of emboli in patients with recurrent or crescendo transient ischaemic attacks using preoperative transcranial Doppler-directed Dextran therapy. *Br J Surg* 2003; **90**: 166–70.
- 39 Jansen C, Vriens EM, Eikelboom BC, Vermeulen FEE, van Gijn J, Ackerstaff RGA. Carotid endarterectomy with transcranial Doppler and electroencephalographic monitoring: a prospective study in 130 operations. *Stroke* 1993; **24**: 665–69.
- 40 Ackerstaff RG, Moons KG, van de Vlasakker, et al. Association of intraoperative transcranial Doppler monitoring variables with stroke from carotid endarterectomy. *Stroke* 2000; **31**: 1817–23.
- 41 Smith JL, Evans DH, Fan L, et al. Interpretation of embolic phenomena during carotid endarterectomy. *Stroke* 1995; **26**: 2281–84.
- 42 Gaunt ME, Martin PL, Smith JL, et al. Clinical relevance of intraoperative embolization detection by transcranial Doppler ultrasonography during carotid endarterectomy: a prospective study of 100 patients. *Br J Surg* 1994; **81**: 1435–39.
- 43 Jansen C, Ramos LMP, van Heeswijk JPM, Moll FL, van Gijn J, Ackerstaff RG. Impact of microembolism and hemodynamic changes in the brain during carotid endarterectomy. *Stroke* 1994; **25**: 992–97.
- 44 Jansen C, Moll FL, Vermeulen FE, van Haelst, Ackerstaff RG. Continuous transcranial Doppler ultrasonography and electroencephalography during carotid endarterectomy: a multimodal monitoring system to detect intraoperative ischemia. *Ann Vasc Surg* 1993; **7**: 95–101.
- 45 Jansen C, Vriens EM, Eikelboom BC, Vermeulen FE, van Gijn J, Ackerstaff RG. Carotid endarterectomy with transcranial Doppler and electroencephalographic monitoring: a prospective study in 130 operations. *Stroke* 1993; **24**: 665–69.
- 46 Hayes PD, Lloyd AJ, Lennard N, et al. Transcranial Doppler-directed Dextran-40 therapy is a cost-effective method of preventing carotid thrombosis after carotid endarterectomy. *Eur J Vasc Endovasc Surg* 2000; **19**: 56–61.
- 47 Naylor AR, Hayes PD, Allroggen H, et al. Reducing the risk of carotid surgery: a 7-year audit of the role of monitoring and quality control assessment. *J Vasc Surg* 2000; **32**: 750–59.
- 48 Levi CR, Roberts AK, Fell G, et al. Transcranial Doppler microembolus detection in the identification of patients at high risk of perioperative stroke. *Eur J Vasc Endovasc Surg* 1997; **14**: 170–76.
- 49 Levi CR, O'Malley H, Fell G, et al. Transcranial Doppler detected cerebral microembolism following carotid endarterectomy: high microembolic signal loads predict postoperative cerebral ischaemia. *Brain* 1997; **120**: 621–29.
- 50 Lennard N, Smith J, Dumville J, et al. Prevention of postoperative thrombotic stroke after carotid endarterectomy: the role of transcranial Doppler ultrasound. *J Vasc Surg* 1997; **26**: 579–84.
- 51 Chan CWM, Tiivas C, Pritchard G, Higman DJ, Imray CHE. Post operative transcranial Doppler monitoring: an early warning device? *Int Angiol* 2000; **19** (suppl 1): 128.
- 52 Kaposzta Z, Martin J, Markus HS. Switching off embolization from symptomatic carotid plaque using S-nitrosoglutathione. *Circulation* 2002; **105**: 1480–84.
- 53 Payne DA, Jones CI, Hayes PD, et al. Beneficial effects of clopidogrel combined with aspirin in reducing cerebral emboli in patients undergoing carotid endarterectomy. *Circulation* 2004; **109**: 1476–81.
- 54 Imray C, Higman D, Tiivas C. Timing of surgery in symptomatic carotid disease. *Lancet* 2004; **363**: 1553–54.
- 55 Imray CHE, Pattinson K. Surgery for carotid artery stenosis: patients with critical stenoses should be admitted to stroke prevention units. *BMJ* 2004; **329**: 1344.